



## Antioxidant effect of lactoferrin on rat liver injury induced by diazinon

Assaraj Q.SH<sup>1</sup>, Alattar H.A.<sup>2</sup>, Farid A.S.<sup>3</sup>, Fararah K.M.<sup>3</sup>

<sup>1</sup> Department of internal medicine, college of veterinary, Bahry University, Sudan.

<sup>2</sup> Department of Animal Mediine, Faculty of Veterinary Medicine, Benha University

<sup>3</sup> Department of Clinical pathology, Faculty of Veterinary Medicine, Benha University

### ABSTRACT

This study is done to evaluate the antioxidant effect of Lactoferrin (LF) on liver injury induced by Diazinon (DZN). Seventy five rats were divided into five groups, each group contains 15 rats; control (G1): (no treatments), Lactoferrin (G2): (LF, 100 mg/kg bw orally daily for 6 weeks), diazinon (G3): (DZN, 70 mg/kg bw orally, daily for 4 weeks), DZN +LF (G4): (DZN, 70 mg/kg bw orally, daily for 4 weeks followed by LF, 100 mg/kg bw orally daily for 2 weeks, and (LF +DZN) group (G5): (LF, 100 mg/kg bw orally daily for seven weeks and DZN, 70 mg/kg bw for four weeks only started at the second week of the experiment). Nitric oxide (NO), Malondialdehyde (MDA), and glutathione peroxidase (GSH-Px) were estimated in liver tissue, in addition to liver sections were taken for histopathological examination. In comparison to control group ( $P < 0.005$ ), NO and MDA in liver tissue were increased significantly, while GSH-Px activities were significantly decreased in DZN group. In LF group NO, MDA levels were significantly decreased ( $P < 0.05$ ), and GSH-Px activities were significantly increased. Compared to DZN group ( $P < 0.001$ ), NO and MDA, in liver homogenate were found decreased significantly in both (DZN+LF) and (LF+DZN) groups, and GSH-Px activities were significantly increased. Histopathological changes in liver tissue induced by DZN were: mild fibrosis with vacular degeneration of hepatocyte, preductal mononeuclear leucocytic cellular infiltrations, and disarrangement of normal hepatic cells with congestion of portal blood vessels. Rats received LF after intoxicated with DZN (DZN+LF group) showed only normal lobular architecture and normal hepatic cells, meanwhile (LF+DZN group) showed: Von kupffer cells proliferation with mild dialatation of central vein.

**Keywords:** Antioxidant, lactoferrin, rat, Liver, diazinon.

(<http://www.bvmj.bu.edu.eg>)

(BVMJ-34(2): 157-168, 2018)

### 1. INTRODUCTION

Environmental pollution induced by organophosphorus insecticide is continuously developing especially in the third world countries, it affecting adversely on human, animal and plants leading to a disaster, nowadays more consideration is poured into the field of non-chemical therapeutics and feed additives, lactoferrin is a natural metal

chelator antioxidant has numerous biological benefits to human and animal health.

Oxidative stress is an imbalance between the systemic manifestation with reactive oxygen species ROS and the ability of biological system to detoxify the ROS or to repair the resulted damage, in human oxidative stress is involved in the development of many serious

diseases such as Asperger syndrome, ADHD, Cancer, Parkinson and Alzheimer's etc (Halliwell and Barry, 2007). Oxidative stress can be induced by environmental factors such as chemicals, UV light, infectious organisms and intrinsically by endogenous factors such as the electron transport chain in mitochondria, some enzyme activities and respiratory bursts from inflammatory cells (Thanan, et al., 2014).

Diazinon (DZN) (0, 0 - diethyl 1 - 0 - [2-isopropyl - 6 - methyl - 4 - pyrimidinyl] phosphorothioate) is a worldwide OP insecticide, used in many different fields concerning agriculture and as a pesticide in domestic uses (Garfitt et al., 2002).

It was puzzle out in Recent studies that acute and chronic toxicity of OPIs depends on induction of oxidative stress through generation of free radicals or reactive oxygen species (ROS) and adversely affect on antioxidants scavenging enzymes in mammals and other organisms in different tissues (Ogutcu et al., 2006).

Lactoferrin (LF), a member of the transferrin family that strongly binds two ferric ions, is mainly found in exocrine secretions, such as colostrum and tears, and in the secondary granules of neutrophils (Masson et al., 1969; Aisen and Listowsky, 1980). Although the primary function of Lf seems to be one of iron transport, many other biologically beneficial effects have been reported, including being an antioxidant, and anti-inflammatory effects (Ishikado et al., 2005; Sandomirsky et al., 2003), anti-bacterial, anti-fungal, anti-viral (Valenti et al., 2004), anti-parasitic (Chierici 2001), anti-tumor activity (Tsuda et al., 2004), immunomodulatory effects (Legrand et al., 2005), (Wakabayashi et al., 2006), and regulation of iron absorption during inflammation and infection (Brock 2002). It is the ability to sequester free ferric ions that gives lactoferrin its potential antioxidant Properties (Larkins 2005).

Diazinon (DZN) is worldwide excessively used insecticides, accused for many environmental and health problems to human, animal, and plants. LF is a naturally exist antioxidant with many beneficial properties, in this study we are trying to explore the antioxidant effect of lactoferrin on oxidative damage induced by DZN.

## 2. Materials and methods

### 2.1. Experimental animals:

Seventy five male Wistar rats weighing about 140-180 gm were obtained from the Animal House, Faculty of Veterinary Medicine, Benha University, Egypt. All animals were caged and maintained on a standard pellets diet, with free access to tap water and were acclimatized for one week before fulfillment of the experiment. Body weights of experimental rats in all the groups were weekly estimated to adjust the dose of applied chemicals using an electronic balance.

### 2.2. Chemicals:

#### *Diazinon (DZN)*

Diazinon 60% (Emulsifiable concentrate) containing 60% active ingredient was obtained from High Control Company, Cairo, Egypt. It was dissolved in distilled water to obtain the required dose concentration (70mg/Kg bw). (El-Shenawy et al., 2010)

#### *Bovine Lactoferrin (LF)*

Bovine Lactoferrin (LF) was provided by Jarrow Formulas (Superior Nutrition and Formulation, Los Angeles). LF was prepared to give a required dose concentration of (100mg/Kg bw) by dissolving LF in distilled water. (Aytül et al., 2010)

### 2.3. Experimental design:

The design is shown in table 1.

### 2.4. Tissue specimens:

Liver specimen was collected from each rat in all groups after sacrificing. Specimens were divided into two parts: 1st part was used for evaluation of hepatic lipid peroxidation (MDA), nitric oxide assay (NO), and antioxidant enzyme glutathione peroxidase (GSH-PX) levels. 2nd part was preserved in neutral buffered formalin solution (10%) for histopathological examination.

### 2.5. Biochemical tests:

#### *Reagents:*

Commercial diagnostic kits were obtained from Biodiagnostic Company for assessment of hepatic lipid peroxidation (MDA), nitric oxide assay (NO), and antioxidant enzyme glutathione peroxidase (GSH-PX) levels through colorimetric methods.

#### *Preparation of tissues homogenate:*

Prior to dissection liver tissue of each rat was perfuse with a PBS (phosphate buffer saline) solution, pH 7.4 containing 0.16 mg/ml heparin to remove any red blood cells. The tissue was homogenized in 5 – 10 cold buffer (i.e, 100 mM potassium phosphate, pH 7.0, containing 2mM EDTA per gram tissue. Was centrifuged at 4,000 rpm for 15 minutes at 4° C. the supernatant was removed for assay.

#### *Nitric oxide (NO):*

Nitric oxide (NO) in liver tissue were measured according to *Montgomery and Dymock (1960)* method.

#### *Malondialdehyde (MDA):*

Lipid peroxidation levels (LPO) in liver tissue were measured according to *Satoh (1978)*, *Ohkawa et al. (1979)*.

#### *Glutathione peroxidase (GSH-Px):*

Glutathione peroxidase activity (GSH-Px) in liver tissue was measured according to the *Paglia and Valentine's (1967)*.

### 2.6. Histopathological specimens:

Specimens for histopathological studies were obtained from all groups and carried out

according to the method of *Banchroft et al., (1996)*.

### 2.7. Statistical analysis:

Data were analyzed using SPSS 11.0 for windows. The significance was calculated using one-way analysis of variance (ANOVA) and followed by Tukey multiple comparison procedure to calculate the significance.  $P < 0.05$  value was taken as statistically significant.

## 3. RESULTS

Rats treated with LF (group 2) showed significant decrease in MDA and NO, significant increase in GSH-PX, in comparison to control group (group 1) at the three collections (5<sup>th</sup>, 6<sup>th</sup>, and 7<sup>th</sup> week).

Rats intoxicated with DZN (group 3) showed significant increase in NO and MDA, and significant decrease in GSH-PX, in comparison to control group (group 1) at the three collections (5<sup>th</sup>, 6<sup>th</sup>, and 7<sup>th</sup> week).

Rats treated with LF after intoxication with DZN (group 4) no significant change in MDA and NO, significant increase in GSH-PX At the second collection (6<sup>th</sup> week), and no significant change in GSH-PX, significant decrease in MDA and NO at the third collection (7<sup>th</sup> week) in comparison to DZN group (group 3).

Rats treated with LF as prevention to toxicity of DZN (group 5) showed significant decrease in MDA and NO, significant increase in GSH-PX, in comparison to DZN group (group 3) at the three collections (5<sup>th</sup>, 6<sup>th</sup>, and 7<sup>th</sup> week).

### *Histological findings:*

Liver sections from control rats figure (1), showed a normal lobular architecture and normal hepatic cells with a well preserved cytoplasm and well defined nucleus and nucleoli. Liver sections from LF treated rats figure (2) showing mild degree of hydropic

degeneration. While liver sections from DZN induced rats Figure (3 and 4) showed mild fibrosis with vacuolar degeneration of hepatocyte, preductal mononuclear leucocytic cellular infiltrations, and disarrangement of normal hepatic cells with congestion of portal blood vessels, Liver sections from rats treated by LF after induction with DZN fig (5)

showed only normal lobular architecture and normal hepatic cells. Liver sections from rats protected by LF against DZN Fig (6) affect showed Von kupffer cells proliferation with mild dilatation of central vein.

Table 1: The design of the experiment.

Groups	No of animal /group	Treatments	Type and time of sampling	Parameters
<b>Control</b>	15	Normal saline for 7 weeks	Tissues samples of liver at the 5 <sup>th</sup> , 6 <sup>th</sup> , and 7 <sup>th</sup> week	<ul style="list-style-type: none"> <li>• GPX</li> <li>• No</li> <li>• MDA</li> </ul>
<b>Diazinon</b>	15	DZN, 70 mg/kg body weight orally in distilled water daily for 4 weeks (2 <sup>nd</sup> to 5 <sup>th</sup> week).		
<b>Lactoferrin</b>	15	LF 100mg/kg orally daily for 6 weeks (2 <sup>nd</sup> to 7 <sup>th</sup> week).		
<b>DZN+LF</b>	15	DZN, 70 mg/kg body weight orally in distilled water daily for 4 weeks (2 <sup>nd</sup> to 5 <sup>th</sup> weeks).  Lactoferin 100mg/kg orally daily for 2 weeks (6 <sup>th</sup> & 7 <sup>th</sup> weeks)		
<b>LF+DZN</b>	15	LF 100mg/kg orally; daily for the 7 weeks.  DZN 70 mg/kg body weight orally for 4 weeks (2 <sup>nd</sup> to 5 <sup>th</sup> weeks).		

**Antioxidant effect of lactoferrin on rat liver injury induced by diazinon**

Table 2: Levels of hepatic LPO, NO, and GSH-PX in control, LF, DZN, DZN+LF, and LF+ DZN groups at 4 weeks post DZN administration. (N=15)

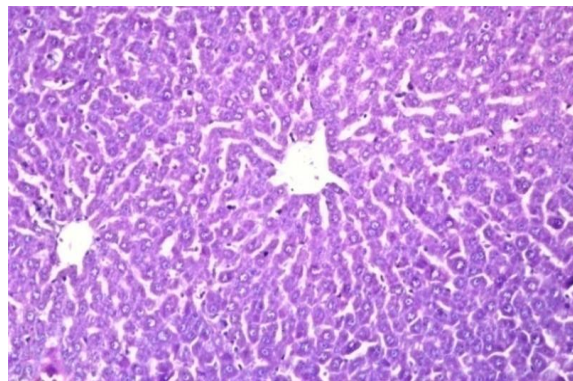
Groups	MDA (nmol/g.T)	GSH-PX (U/g.T)	NO (μmol/L)
G1 (Control)	593.58 ±52.13 <sup>b</sup>	5336.71 ±49.21 <sup>c</sup>	23.93 ±1.28 <sup>c</sup>
G2(LF)	565.06 ±23.66 <sup>c</sup>	5858.09 ±28.90 <sup>a</sup>	16.05 ±1.13 <sup>d</sup>
G3 (DZN)	633.16 ±29.25 <sup>a</sup>	4764.45 ±115.60 <sup>d</sup>	62.39 ±1.07 <sup>a</sup>
G4 (DZN+LF)	633.16 ±29.25 <sup>b</sup>	4764.45 ±115.60 <sup>d</sup>	62.39 ±1.07 <sup>a</sup>
G5 (LF+DZN)	579.58 ±36.72 <sup>b</sup>	5465.11 ±57.80 <sup>b</sup>	32.37 ±1.66 <sup>b</sup>

Table 3: Levels of hepatic LPO, NO, and GSH-PX in control, LF, DZN, DZN+LF, and LF+ DZN groups at 5 weeks post DZN administration. (N=15)

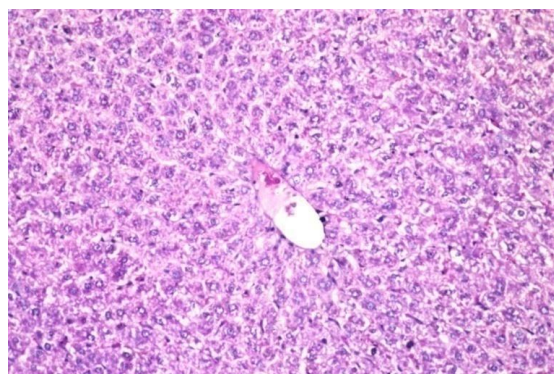
Groups	MDA (nmol/g.T)	GSH-PX (U/g.T)	NO (μmol/L)
G1 (Control)	500.67 ±26.81 <sup>b</sup>	5077.33 ±6.15 <sup>d</sup>	31.05 ±0.74 <sup>c</sup>
G2(Lactoferrin)	327.28 ±46.88 <sup>d</sup>	5928.15 ±26.70 <sup>a</sup>	18.06 ±0.88 <sup>d</sup>
G3 (Diazinon)	583.32 ±57.17 <sup>a</sup>	4779.68 ±60.69 <sup>e</sup>	69.23 ±0.91 <sup>a</sup>
G4 (DZN+LF)	590.16 ±50.06 <sup>a</sup>	5300.61 ±46.24 <sup>c</sup>	67.31 ±2.98 <sup>a</sup>
G5 (LF+DZN)	472.13 ±40.78 <sup>c</sup>	5608.01 ±48.93 <sup>b</sup>	49.00 ±0.51 <sup>b</sup>

Table 4: Levels of hepatic LPO, NO, and GSH-PX in control, LF, DZN, DZN+LF, and LF+ DZN groups at 6 weeks post DZN administration. (N=15)

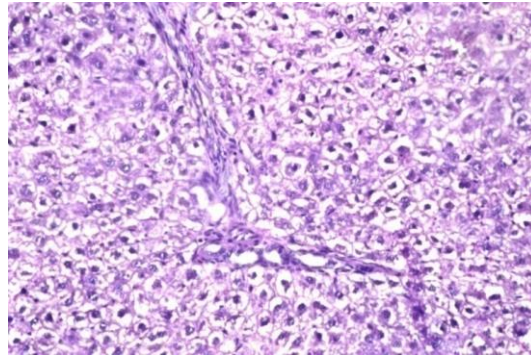
Groups	MDA (nmol/g.T)	GSH-PX (U/g.T)	NO ( $\mu$ mol/L)
G1 (Control)	434.94 $\pm 46.06^b$	5982.98 $\pm 34.03^c$	27.78 $\pm 0.67^c$
G2(Lactoferrin)	322.58 $\pm 44.94^d$	6351.59 $\pm 122.70^a$	19.47 $\pm 0.58^d$
G3 (Diazinon)	510.91 $\pm 22.94^a$	5885.50 $\pm 22.80^d$	57.41 $\pm 1.42^a$
G4 (DZN+LF)	414.65 $\pm 21.91^c$	5873.31 $\pm 126.72^d$	47.65 $\pm 2.70^b$
G5 (LF+DZN)	298.39 $\pm 39.47^e$	6126.60 $\pm 202.82^b$	45.94 $\pm 1.83^b$



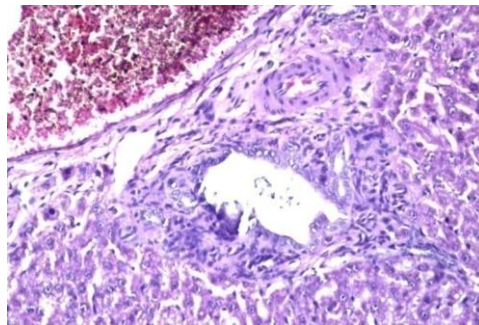
**Fig.1.** Control group: no histopathological alteration and the normal histological structure of the central vein and surrounding hepatocytes in the parenchyma.



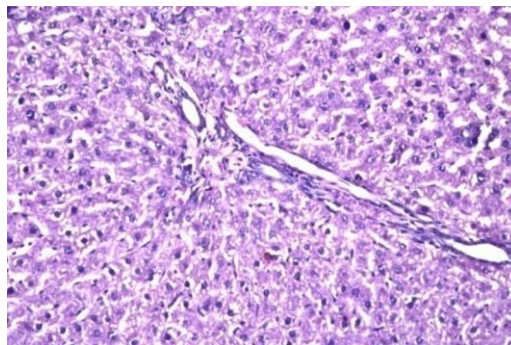
**Fig.2.** Lactoferrin group: no histopathological alteration recorded.



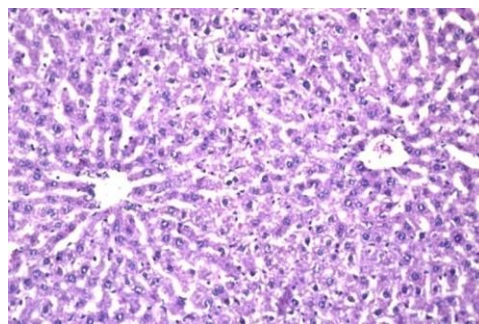
**Fig.3.** Mild fibrosis with vacuolar degeneration of hepatocyte, preductal mononeuclear leucocytic cellular infiltrations, and disarrangement of normal hepatic cells with congestion of portal blood vessels.



**Fig.4.** There was congestion in the portal vein as well as periductal fibrosis with inflammatory cells infiltration surrounding the bile ducts.



**Fig.5.** Group induced by diazinon and treated by the lactoferrin (DZN +LF): Fine fibrosis was detected in the portal area.



**Fig.6.** Group of rats protected by lactoferrin (LF + DZN): Von kupffer cells proliferation with mild dilatation of central vein.

#### 4. DISCUSSION

The liver is a major target organ for chemicals and drugs. Hepatotoxicity therefore is an important end point in the evaluation of the effect of particular xenobiotics. MDA is the end product of lipid peroxidation (LPO), which is an autocatalytic process caused by free radicals. MDA is an important indicator of LPO levels (Kalender et al., 2005) The present study revealed an increased LPO levels in the liver tissue induced by DZN evinced by the increased MDA levels, thus this increase of MDA levels in this study is an indicator of free radical formation by DZN in liver tissue of rats, denoting the oxidative stress induced by DZN administration. Endogenous nitric oxide (NO) is formed from the amino acid L-arginine with nitric oxide synthesis (NOS) enzyme. Increased level of NO has a main role in the modulation of oxidative stress and tissue damage (Tutanc et al., 2012). It was reported that oxidative stress results in the increase of the activity of NO synthase, as a consequence to the elevation of NO release (Peresleni et al., 1996). In this study, DZN administration induced oxidative stress proved by the increased NO and MDA concentrations, That in comparison to control group rats intoxicated with diazinon (group 3) showed significant increase in MDA and NO levels at the three collections (5<sup>th</sup>, 6<sup>th</sup>, and 7<sup>th</sup> weeks). These results were correlated with previous reports of Messarah et al., (2013) who showed that DZN might generate ROS. Also agrees with Hazarika et al., (2003) who recorded that Organophosphorus compounds caused an increase in the level of LPO, Gultekin et al., (2001) ; Altuntas et al., (2002c); Altuntas et al., (2003); Altuntas et al., (2004) They mentioned that in previous in vitro and in vivo studies, MDA formation increased by the administration of Chlorpyrifos-ethyl, Fenthion, Phosalone and Diazinon. The increase in MDA formation

may be modulated by DZN itself inducing LPO or by a possible increase in ROS induced by it (DZN).

The antioxidant activity of bovine lactoferrin (LF) has been demonstrated in different biological and chemical environments. Bovine LF has been reported to lower lipid peroxidation by decreasing the conversion of H<sub>2</sub>O<sub>2</sub> to OH by the Fenton reaction by sequestering iron (Shinmoto et al., 1992) this was clear in the present study, that the three groups administered with lactoferrin (group 2, group 4, and group 5) showed significant decrease in MDA and NO accompanied by significant increase in GSH-PX, through the three collections (5<sup>th</sup>, 6<sup>th</sup>, 7<sup>th</sup> weeks).

MDA is a main sign of endogenous lipid peroxidation and the activity levels of the antioxidant enzymes GSH-PX, SOD and CAT. In the current study, treatments with LF decreased the MDA levels in liver tissue of rats. Although a various mechanisms contribute in protection against ROS-mediated cell and tissue injury, intracellular AOE GSH-PX are considered to play a major role; while SOD converts superoxide to H<sub>2</sub>O<sub>2</sub>. GSH-PX and CAT modulate the conversion of H<sub>2</sub>O<sub>2</sub> to H<sub>2</sub>O. GSH-PX can also degrade lipid peroxides. So the antioxidative status of rat liver tissue was assessed by estimation of the GSH-PX enzyme. In the present study, GSH-PX activities in liver tissue substantially increased in rats administered with LF.

Findings of the present study proves the antioxidant activity of LF against the oxidative stress induced by DZN, thus agrees with Shinmoto et al., (1992) and Raghuveer et al., (2002) who recorded that Supplementation of LF in the diet of preterm infants also attenuated iron-induced oxidation products, Britigan et al., (1986) also recorded that LF is thought to serve as an antioxidant



since iron bound to the protein is unable to participate as a catalyst for the generation of the hydroxyl radical. Satue-Gracia et al., (2000) recorded that LF might also be considered as an oxidative stress detoxificant.

In our current study NO and MDA levels in liver tissue of rats intoxicated with diazinon (group 3) were obviously increased when compared to control group (group 1), suggesting a significant liver damage induced by DZN. This liver damage was proved by histopathological examination done to liver tissue specimens of these rats' (group 3); periductal cellular infiltrations; degenerative changes of hepatic cells with lymphocyte infiltration, cell necrosis, pyknotic nuclei, and disarrangement of normal hepatic cells, congestion of portal tract, sinusoidal dilation, showed by the histoarchitecture of liver sections of these rat. This result of our study agrees with El – Shenawy et al., (2010) ; Moss et al., (2011) they mentioned that significant damage in the hepatic cells in liver was observed as the result of DZN administration, and also agrees with a study done to evaluate the adverse effect of exposure to Diazinon on male rats by Abdel-Tawab et al., (2012); found that, histopathological changes in liver specimens from rats intoxicated by DZN are in correlation with examination of liver function; that necrotic conditions observed in these liver specimens were in corroboration with the observed increased level of lipid peroxidation. And agrees also with Hilal et al., (2015), he recorded an increased levels of ALT, AST, NO, and MPO accompanied with cellular infiltrations; mononuclear cellular infiltration in the portal area, severe vaculation, disarrangement of normal hepatic cells, congestion of portal tract, severe sinusoidal dilation in rats intoxicated with DZN.

In contrast lactoferrin reduces the levels of NO and MDA in the three groups of rats treated with lactoferrin; lactoferrin group (group 2) (in comparison to control group) DZN +LF group (group 4) and LF + DZN group (group 5) in comparison to DZN group. These findings of liver function examination also showed a correlation with the histopathological findings of the same rats; liver sections from lactoferrin treated rats showed no histopathological alteration, while liver sections from rats treated by lactoferrin after induction with Diazinone showed only fine fibrosis with normal lobular architecture and normal hepatic cells with a well preserved cytoplasm and well defined nucleus and nucleoli, meanwhile liver sections from rats protected by lactoferrin against DZN toxicity showed diffuse kupffer cells proliferation in between the hepatocytes. Our present study ravel out that LF has a modulatory but better protective effect on liver damage induced by DZN.

In conclusion, Lactoferrin has a protective, antioxidant and modulator effect on liver injury induced by diazinon. Using lactoferrin as feed additive (protection) against oxidative stress induced by diazinone is more beneficial than utilizing it as a treatment drug.

Further studies for LF and other naturally occurred antioxidants should be paid more attention, insecticides hazards should be well considered.

## 5. REFERENCES

- Abdel-Tawab H. Mossa, Tarek M. Heikal and Enayat Abdel Aziz Omara. (2012). Physiological and histopathological changes in the liver of male rats exposed to paracetamol and diazinon Asian Pacific Journal of Tropical Biomedicine :S1683-S1690

- Aisen, P., Listowsky, I., (1980). Iron transport and storage proteins. *Annu. Rev. Biochem.* 49, 357–393.
- Altuntas, I., Delibas, N., Can, M., Yonden, Z., Orhan, H. and Sutcu, R., (2002c). Effects of organophosphate insecticide fenthion on lipid peroxidation and antioxidant enzymes in erythrocyte (in vitro). *Ibni Sina Dergisi* 7, 90–95.
- Altuntas, I., Delibas, N., Doguc, D.K., Ozmen, S. and Gultekin, F., (2003). Role of reactive oxygen species in organophosphate insecticide phosalone toxicity in erythrocytes in vitro. *Toxicology in Vitro* 17, 153–57.
- Altuntas, I., Kilinc, I., Orhan, H., Demirel, R., Koylu, H. and Delibas, N., (2004). The effects of diazinon on lipid peroxidation and antioxidant enzymes in erythrocytes. *Human and Experimental Toxicology* 23, 9–13.
- Banchroft Johnd. and Stevens A Lan, (1996). *Theory and practice of histological techniques*. 5th ed. Edinburgh: Churchill Livingstone Pub; 2002. p. 172–5 [p.593–620]
- Britigan, B.E., Rosen, G.M., Thompson, B.Y., Chai, Y., Cohen, M.S., (1986). Stimulated neutrophils limit iron-catalyzed hydroxyl radical formation as detected by spin trapping techniques. *J. Biol. Chem.* 261, 17026–17035.
- Brock J. (2002). The physiology of lactoferrin. *Biochem Cell Biol*;80(1):1-6.
- Chierici R. (2001). Antimicrobial actions of lactoferrin. *Adv Nutr Res*; 10:247-69.
- El-Shenawy N.S., El-Salmy F., Al-Eisa R.A., and El-Ahmary B., (2010). Amelioratory effect of vitamin E on organophosphorus insecticide diazinon-induced oxidative stress in mice liver. *Pesticide Biochem. Physiol.* 96: 101-107.
- Garfitt, S.J., Jones, K., Mason, H.J., Cocker, J., (2002). Exposure to the organophosphate diazinon: data from a human volunteer study with oral and dermal doses. *Toxicol. Lett.* 134, 105–113.
- Gultekin F., Delibas N., Yasar S., Kilinc I., (2001). In vivo changes in antioxidant systems and protective role of melatonin and a combination of vitamin C and Vitamin E on oxidative damage in erythrocytes induced by chlorpyrifos-ethyl in rats. *Arch Toxicol.*;75:88–96.
- Halliwell, Barry (2007). "Oxidative stress and cancer: have we moved forward?" (PDF) *Biochem. J.*401 (1):1 11. doi: 10. 1042 / B J 2006 1131 . PMID17150040
- Hilal Beydilli, ; Nigar Yilmaz 2; Esin Sakalli Cetin 3; Yasar Topal 4; Ozgur Ilhan Celik 5; Cem S (2015). Evaluation of the Protective Effect of Silibinin Against Diazinon Induced Hepatotoxicity and Free-Radical Damage in Rat Liver. DOI: 10.5812/ircmj.17(4).25310.
- Hazarika A., Sarkar S.N., Hajare S., Kataria M., Malik J.K., (2003). Influence of malathion pretreatment and the toxicity of anilofos in male rats: a biochemical interaction study. *Toxicology* 185, 1-8.
- Ishikado, A., Imakana, H., Takeuchi, T., Harada, E., Makino, T., (2005). Liposomalization of lactoferrin enhanced it's anti-inflammatory effects via oral administration. *Biol. Pharm. Bull.* 28, 1717–1721.
- Kalender S., Ogutcu A., Uzunhisarcikli M., Acikgoz, F., Durak D., Ulusoy Y., Kalender Y., (2005a). Diazinon-induced hepatotoxicity and protective effect of Vitamin E on some biochemical indices and ultra structural changes. *Toxicology* 211, 197–206.
- Larkins N., (2005). Potential implications of

- lactoferrin as a therapeutic agent. *Am J Vet Res*; 66 (4): 739 - 42.
- Legrand D, Ellass E, Carpentier M, Mazurier J. (2005). Lactoferrin: a modulator of immune and inflammatory responses. *Cell Mol Life Sci* ; 62 (22) : 2549-59.
- Masson, P.L., Heremans, J.F., Schonke, E., (1969). Lactoferrin, an iron-binding protein in neutrophilic leukocytes. *J. Exp. Med.* 130, 643–658.
- Messarah M, Amamra W, Boumendjel A, Barkat L, Bouasla I, Ab-dennour C, et al., (2013). Ameliorating effects of curcumin and vitamin E on diazinon-induced oxidative damage in rat liver and erythrocytes. *Toxicol Ind Health.*;29(1):77–88.
- Montgomery, H. A.C and Dymock, J. F (1960) *Analyt*, 86,414
- Mossa AH, Refaie AA, Ramadan A, (2011). Effect of exposure to mixture of four organophosphate insecticides at No Observed Adverse Effect Level (NOAEL) dose on rat liver: the protective role of vitamin C. *Res. J. Envir. Toxicol.* 2011; 5: 323-5.
- Ogutcu A, Uzunhisarcikli M, Kalender S, Durak D, Bayrakdar F, Kalender Y, (2006). The effects of organophosphate insecticide diazinon on malondialdehyde levels and myocardial cells in rat heart tissue and protective role of vitamin E, *Pesticide Biochem. Physiol.* 86 93–98
- Ohkawa, H., Ohishi W, and Yagi K. (1979). *Anal. Biochem* 95, 351
- Paglia D E. and Valentine's W N. (1967). Studies on the quantitative and qualitative characterization of erythrocyte glutathione peroxidase. *J. Lab. Clin. Med.* 70(1): 158- 69.
- Peresleni T, Noiri E, Bahou WF, Goligorsky MS. (1996). Antisense oligodeoxy nucleotides to inducible NO synthase rescue epithelial cells from oxidative stress injury. *Am J Physiol.*; 270 (6 Pt 2): F971–7.
- Raghuveer TS, McGuire EM, Martin SM, Balansky RM, Noonan D, Albin A. (2002). Lactoferrin in the preterm infants diet attenuated iron-induced oxidation products. *Pediatr Res*;52:964–72.
- Sandomirsky, B.P., Galchemko, S.E., Galchenko, K.S., (2003). Antioxidative properties of lactoferrin from bovine colostrums before and after its lyophilization. *Cryoletters* 24, 275–280.
- Satoh K, *Clinica Chemica Acta* (1978), 90, 37.
- Satue-Gracia, M.T, Frankel, E.N, Rangavajhyala, N., German, J.B., (2000). Lactoferrin in infant formulas: effect on oxidation. *J. Agric. Food Chem.* 48, 4984–4990.
- Shinmoto H, Dosako S, Nakajima I, (1992). Antioxidant activity of bovine lactoferrin on iron ascorbate induced lipid peroxidation. *Biosci Bio-technol Biochem*; 56: 2079–80.
- Thanan R, Oikawa S, Hiraku Y, Ohnishi S, Ma N, Pinlaor S, Yongvanit P, Kawanishi S, Murtada M. (2014). Oxidative stress and its significant roles in neurodegenerative diseases and cancer. *Int J Mol Sci*: 16(1): 193-217. doi:10.3390/ijms 16010193.
- Tsuda H., Ohshima Y., Nomoto H., Fujita K., Matsuda E., Iigo M., (2004). Cancer prevention by natural compounds. *Drug Metab Pharmacokinet*; 19 (4):245-63.
- Tutanc M, Arica V, Yilmaz N, Nacar A, Zararsiz I, Basarslan F, (2012). Effects of erdosteine on cyclosporin-A-induced nephrotoxicity. *Hum Exp Toxicol.*; 31(6):565–73.
- Valenti P., Berlutti F., Conte M., Longhi C., Seganti L., (2004). Lactoferrin

functions: current status and perspectives. *J Clin Gastroenterol*; 38 (6 Suppl): S127-9.

Wakabayashi H, Takakura N, Yamauchi K, Tamura Y, (2006). Modulation of immunity related gene expression in small intestines of mice by oral administration of lactoferrin. *Clin Vaccine Immunol*; 13(2): 239-45.