



TOXICITY OF LAMBDA CYHALOTHRINE ON ERYTHROGRAM, LIVER AND KIDNEY WITH MOLORATED BY VITAMINE C.

Rania M. Waheed, Bakery, H.H., El-Shawarby, R.M. and Abou Salem, M.E.

Department of Forensic Medicine and Toxicology. Fac. Vet. Med., Benha University

ABSTRACT

Lambda cyhalothrin is a new pyrethroid insecticide used all over the world to control the insect on wide rang in a variety of crops, and used as vector control (mosquito). The present study was designed to investigate the protective effect of vitamin C on the toxicological effects of lambda cyhalothrin on erythrogram, liver and kidney enzyme activities and histopathological changes. In this study 80 male albino rats (western strain) were divided in to 4 groups each group contain 20 rats. First group kept as control, second group was given vitamin C at dose 200ppm in drinking water daily for 2 month, third group was given 100 mg/kg/B.w lambda cyhalothrine 3 day per week for 2 month orally by using stomach tube while fourth group was given lambda cyhalothrine at dose 100mg/kg/Bw three time/week orally by stomach tube plus vitamin C 200ppm in distal ill water daily continuously for 2 month. The obtained results were significant decrease on erythrocyte, hemoglobin and pcv% in group of rats received lambda cyalothrine. While ALT, AST, AP, creatinine, urea and uric acid were significantly increased but the total protein, albumin and globuline were significantly decreased in rats received-lambda cyhalothrine in compared with other groups. This parameters were non-significant difference in control group and group received vitamin C but improved in the group rats received lambda cyhalothrine plus vitamin C.

KEY WORDS: Erythrogram, Insecticide, Lambda cyhalothrin, Liver, Kidney.

(BVMJ 22(2): 238-248, 2011)

1. INTRODUCTION

Today the use of pesticides in agriculture has been increasing steady. The harmful effects of many pesticides, such as orgariophosphrous, organochlorin and carbamates, have led to use of pyrethroids as alteratives. Pyrethroids analogs of naturally occurring pyrethrine and widely used in agriculture in many countries [19]. Lambda cyhalothrine (LCT) an insecticide registered by U.S Environmental Protection Agency [28] it belongs to pyrethroids. Lambda cyhalothrine products come in various forms including powder, pellets, liquids, small capsules and ear tags containing the chemical. Lambda cyhalothrine is wide use in agricultural insecticide for the food and

non-food crops. Also it used insecticide indoor and outdoor for homes, hospitals and other buildings. Vitamin C is an essential nutrient required by the body for the development and maintenance of scar tissue, blood vessels, and cartilage. Vitamin C is also necessary for creating ATP, dopamine, peptide hormones, and tyrosine. As a powerful antioxidant, vitamin C helps reduction oxidative stress on the body. Lambda cyhalothrine when given to rat orally at dose 150mg/kg B.w. daily for one week, showed slightly increase rectal temperature and significant suppression in body weight gain [21]. Lambda cyhalothrine administrated to rat at dose 150mg/kg B.w 3day per week for 2 month showed increase of transaminase

enzymes alanine amino transferase (ALT) & aspartate amino transferase (AST) [10].

2. MATERIAL AND METHODS

2.1. *Experimental animals*

Eighty apparently healthy male albino rats (western strain) weighted (240- 250gm) were obtained from veterinary serum and vaccine research institute, Abbasia Cairo, Egypt. The animals housed in stainless steel were bottom cage and kept under constant environmental condition & fed on fresh standard pellet & given tap water. All animals were acclimatized for one week before the beginning of the experiment.

2.2. *Experimental design*

In this study 80 male albino rats (western strain) were divided into four groups each one contains 20 rats. First group kept as control, second group was given vitamin C at dose 200ppm in drinking water daily for two months, third group given 100mg/kg/B.w lambda cyhalothrin 3 days per week for 2 months, according to [22] orally by using stomach tube, while fourth group was given lambda cyhalothrin at dose 100mg/kg/Bw three times/week orally by stomach tube plus vitamin C 200ppm in drinking water daily continuously for 2 months according to [30].

2.3. *Sampling:*

Half of rats in each group were sacrificed after first month and the other half after second month. Whole blood collected in clean dry heparinized tubes for erythrogram. Blood samples collected in centrifuge tubes, allowed to stand for one hour at room temperature till clotted and centrifuged at 3000 rpm for fifteen minutes for serum separation, and then kept at -20°C for biochemical analysis.

2.4. *Biochemical analysis*

Serum ALT and AST were performed according to [27]. Alkaline phosphates (AP) [4], Total protein, albumin, urea and Creatinine [16] and uric acid [18] were estimated as described previously.

2.5. *Histopathological examination*

Samples were taken from liver and kidney of different groups of rats. Liver and kidney samples were kept in formalin 20% for histopathological examinations using light microscope [2].

2.6. *Statistical analysis*

The statistical analyses were done by one way ANOVA and DUNCAN test using SPSS program version 11. P value < 0.05 was assumed for statistical significance.

3. RESULTS

3.1. *Effect of vit. C and / or lambda cyhalothrin on erythrocytic count, hemoglobin concentration & packed cell volume in adult male albino rats* showed in Table (1) & Fig (1&2). The data of erythrocytic count (RBCs), hemoglobin concentration (Hb) & packed cell volume (PCV) of rats in different experimental groups were shown in table (1) and figure (1&2).

The rats in group HI received lambda cyhalothrin showed significant decrease in RBCs count in compared with other experimental groups after 4th and 8th weeks of experiment. While the rats of group I (control) showed significant increase in RBCs count after 4th and 8th weeks.

There was no statistical difference in RBCs count in rats of group II and group IV after 4th week. Concerning Hb concentration (after 4th and 8th week of experiment) there was significant decrease in Hb concentration of rats in group .El fats-received lambda cyhalothrin. There were no statistical differences between rats in group I (control) and group II, received vit. C, which showed the increased value followed by that of group IV, received lambda cyhalothrin plus vit C after 4th

week of experiment. While after 8th week of experiment, there were no statistical differences between rats in group I (control), group II, received vit. C and group IV, received lambda cyhalothrin plus vit C.

Regarding to PCV (%), after 4th week of experiment, there was significant increase in PCV % of rats in group I (control), followed by rats in group II received vit. C and group IV, received lambda cyhalothrin

plus vit C. While rats in group III, that administrated lambda cyhalothrin showed significant decrease in PCV %. While after 8th week of experiment rats in group III, received lambda cyhalothrin showed significant decrease in PCV % in compared with other experimental groups. There were no statistical differences between rats in group II, received vit. C & group IV, received lambda cyhalothrin plus vit C.

Table 1 Effect of vit C and/or lambda cyhalothrin on erythrocytic count, Hb concentration and PCV% in adult male albino rat (mean± S.D.).

Parameters	Weeks	Group I	Group II	Group III	Group IV
RBCs count (x10 ⁶ /μL)	4th	7.92±0.10C	7.32±0.08b	6.50±0.13a	7.04±0.27b
	8th	7.84±0.25C	7.52±0.14bc	6.14±0.07a	7.00±0.23b
Hb concentration (g/dL)	4th	14.36±0.23C	14.20±0.11C	11.02±0.36a	13.14±0.32b
	8th	13.66±0.27b	14.06±0.21b	11.00±0.33a	13.62±0.19b
PCV (%)	4th	38.70±0.20d	36.04±0.28C	31.58±0.49a	34.36±0.76b
	8th	38.48±0.24C	36.90±0.41b	31.10±0.55a	36.42±0.62b

Mean with different litters at the same raw differs significant (P<0.05).

The data of ALT, AST and AP on serum of rats in different experimental groups were shown in table (2) and figure (3&4). The level of ALT in group III (rats received Lambada cyhalothrine) showed significant increase in compared with other experimental groups at 4th & 8th weeks of experiment. At 4th week of experiment there was no statistical differences between group I (control) and II(rat received vit.c) which showed the lower level of ALT in serum of rats followed by ALT of group IV (rat received Lambada cyhalothrine plus vit.c). While the level of ALT in serum of rats at 8th week of experiment, there were no statistical differences between group I (control), II (rat received vit.c) and group IV (rat received Lambada cyhalothrine plus vit c.). The level of AST at 4th week of experiment showed significant increase in group III (rats recived Lambada cyhalothrine) and while in there were no statistical differences in level of AST in serum of rats in group I (control),group II (rat received vit.c and group IV (rat received Lambada cyhalothrine plus vit c.)

after 4th week of experiment. After 8th week of experiment the level of AST showed significant increase in group III (rats received Lambada cyhalothrine) followed by group IV that administrated Lambada cyhalothrine plus vit. C but there was no statistical differences between group I (control) and group II (rat received vit.c) that showed lower level of AST in serum of rats after 8th week of experiment.

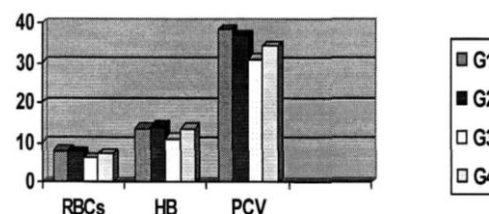


Fig 1 RBCs, Hb and MCV in different group at 1 month from the beginning of experiment.

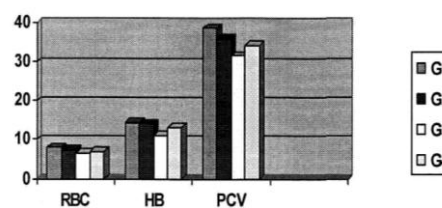


Fig 2 RBCs, Hb and PCV in different group at 2 month from the beginning of experiment.

After 4th and 8th weeks of experiment, there was significant increase in the level of AP in serum of group III (rats received Lambada cyhalothrine) which followed by group IV that administrated Lambada

cyhalothrine plus vit C. There no statistical differences in level of AP of rats in group I (control), group II (rat received vit.c) and group IV (rat received Lambada cyhalothrine plus vit c).

Table 2 Effect of vit C and/or Lambada cyhalothrine on ALT, AST, AP in adult male albino rat (mean± SD).

Parameters	Weeks	Group I	Group II	Group III	Group IV
ALT u/1	4 th	56.2±1.82 ^a	52.6±2.78 ^a	88.2±1.88 ^C	68.6±3.72 ^b
	8 th	65.6±2.50 ^a	63.0±1.92 ^a	100.8±3.81 ^b	70.4±3.69 ^a
AST u/1	4 th	24.9±1.57 ^a	25.6±1.36 ^a	38.6±2.72 ^b	29.9±3.34 ^a
	8 th	27.2±0.19 ^a	27.2±0.94 ^a	58.6±1.66 ^C	38.4±1.75 ^b
AP u/1	4 th	76.3±0.88 ^a	74.0±0.57 ^a	122.6±2.90 ^C	95.6±1.45 ^b
	8 th	75.6±0.88 ^a	73.6±0.88 ^a	127.0±1.73 ^C	88.6±1.45 ^b

Mean with different litters at the same raw differs significant (P<0.05).

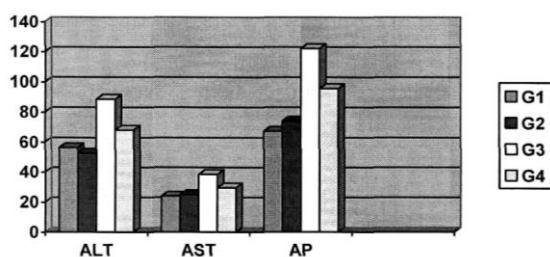


Fig. 3 Level of ALT (U\L),AST(U\L)and AP(U\L) in rats serum at 1 month from the beginning of the experiment.

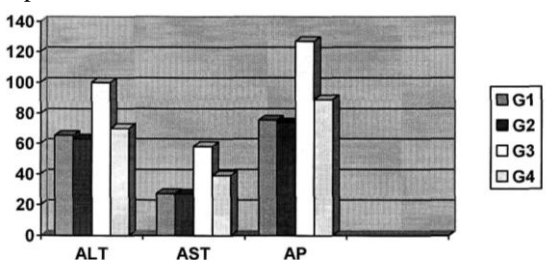


Fig. ALT (U\L), AST (U\L) and AP (U\L) in rats serum at 2 month from the beginning of the experiment.

3.2. *Effect of vit C and/or Lambada cyhalothrine on total protein and albumine and globuline in serum of adult male albino rat.* showed in Table (3) & Fig (5&6)

The total protein in serum of rats showed significant decrease in group III (rats received Lambada cyhalothrine) in compared with other experimental groups at 4th and 8th week of experiment. There was no statistical difference in total serum

protein between group I (control) and group II (rat received vit. C) that showed the higher level of total protein followed by total protein in group IV (rat received Lambada cyhalothrine plus vit c).

The rats in group III, (rats received Lambada cyhalothrine) showed significant decrease in albumin level in serum of rats compared with other experimental groups at 4th and 8th weeks of experiment. There were no statistical differences between groups in level of serum albumin in group I (control), group II (rat received vit.c), group IV (rat received Lambada cyhalothrine plus vit.c) at 4th & 8th weeks of experiment.

Rats in group III (rats received Lambada cyhalothrine) & group IV that administrated lambda cyhalothrin plus vit C. showed significant decrease in globuline level in compared with other experimental groups. The rats in group II that administrated vit C. showed higher level of serum globuline in compared to other experimental groups at 4th week of experiment.

After 8th week of experiment, the level of globuline in serum of rats in group III (rats received Lambada cyhalothrine) and group IV (rat received LCT plus vit c.) showed significant decrease in compared to other experimental groups.

There was no statistical difference in level of serum globuline of rats between group I

(control) & group II (rat received vit.c) which showed higher level of globuline

after 8th week of experiment.

Table (3): Effect of vit C and/ or Lambada cyhalothrine on total protein and albnmine & globuline in adult male albino rat (mean±SD).

Parameters	Weeks	Group I	Group II	Group III	Group IV
Total protein g/dl	4 th	5.91±0.04 ^C	5.90±0.03 ^C	4.43±0.17 ^a	5.56±0.03 ^b
	8 th	6.06±0.03 ^C	5.96±0.12 ^C	4.48±0.04 ^a	5.61±0.11 ^b
Albumine g/dl	4 th	4.21±0.02 ^b	4.12±0.02 ^b	3.03±0.03 ^a	4.10±0.06 ^b
	8 th	4.35±0.10 ^b	4.33±0.09 ^b	3.40±0.08 ^a	4.30±0.06 ^a
Globuline g/dl	4 th	1.70±0.03 ^{ab}	1.78±0.04 ^b	1.40±0.15 ^a	1.46±0.09 ^a
	8 th	1.71±0.08 ^b	1.63±0.03 ^b	1.08±0.03 ^a	1.31±0.15 ^a

Mean with different litters at the same raw differs significant (P<0.05).

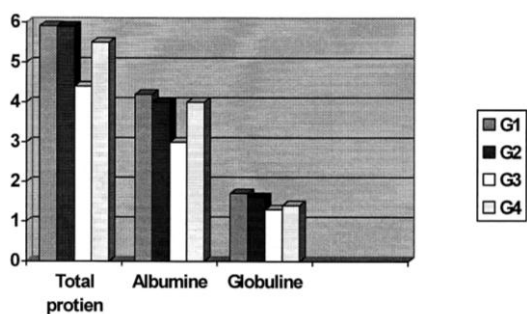


Fig. 5 levels of total protein,albumine and globuline of rats in different groups at 1 st month of experiment.

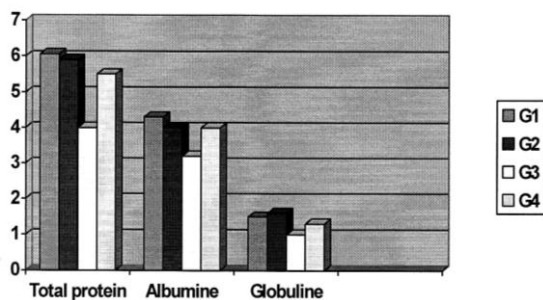


Fig. 6 Levels of total protein. albumine and globuline of rats in different group at 2nd month of experiment.

3.3. Effect of vit C and/or Lambada cyhalothrine levels of serum on urea, uric acid and creatinin in serum of adult male rats, showed in Table (4) & Fig (7&8)

Urea, uric acid and creatinine in serum of rats showed significant increase in group III (rats received Lambada cyhalothrine) at 4th and 8th week of experiment in compared with other experimental groups. There were no statistical differences in level of urea, uric acid, creatinine in serum of rats between group I (control) & group II rat received vit.c at 4th & 8th weeks of

experiment which showed lower level of urea, uric acid and creatinine.

The levels of urea, uric acid and creatinine in serum of rats in group IV rat received Lambada cyhalothrine plus vit.c were higher than that of group I (control) and group II (rat received vit. C) at the 4th and 8th weeks of experiment.

Histopathological examination of liver and kidney in rats of control group and group rats received vitamine c observed the normal histological structure of the examined organs. The histophological findings in organs of rats received lambda cyhalothrin showed histophological changes that were more sure after 8th week of experiment when compared with that observed after 4th week. The examined organs of rats received lambda cyhalothria plus vitamin C showed less or no histophoogical findings.

No histophological findings were observed in liver of both control group I and group II (rat received vitamin C). And the normal histological structure of the central veins and surrounding hepatocytes were recorded along the time of experiments at 4th weeks of experiment photo (1).

After 4th week the microscopical examination of liver in group III (rats received lambda cyhulomrin revealed dilation and cargestion of the portal veins (photo 1). Vacuolar and hydropic degeneration of the hepatocytes, characterized by swollen pale vacuolated cytoplasm, were commonly observed particularly in the priportal areas.

Table 4 Effect of vit C and/or Lambada cyhalothrine on levels of serum on urea, uric acid and creatinin in serum of adult male rats (mean±SD).

Parameters	Weeks	Group I	Group II	Group III	Group IV
Urea (mg/dl)	4th	30.56±0.29a	30.03±0.29a	44.50±0.28C	33.00±0.57b
	8th	31.43±0.35a	31.10±0.67a	53.50±0.29C	33.96±0.29b
Uric-acid (mg/dl)	4th	1.80±0.07a	1.82±0.04a	2.54±0.09C	2.10±0.05b
	8th	1.76±0.08a	1.74±0.09a	2.76±0.09C	2.10±0.03b
Creatinine (mg/dl)	4th	0.47±0.12a	0.47±0.14a	0.64±0.06C	0.53±0.06b
	8th	0.49±0.06a	0.48±0.09a	0.83±0.09C	0.57±0.06b

Mean with different litters at the same raw differs significant (P<0.05).




Fig. 7 Level of serum urea, uric acid and creatinine of rats in different groups at 1st month of experiment.




Fig. 8 Level of serum urea, uric acid and creatinine of rats in different groups at 2nd month of experiment.

After 8th rats received lambda cyhalothrin livers showed congestion and dilation of portal veins, central veins and hepatic sinusoids. Multifocally and randomly affecting large areas of normal architecture, there were degeneration changes of hepatocytes photo (2). Moreover, multifocal areas of coagulative and lytic necrosis of hepatocytes were also detected in few cases). Coagulative necrosis was characterized by retention of hepatic cord architecture and shrunken, often individualized, hepatocytes with hypereosinophilic cytoplasm and pyknotic nuclei, meanwhile lytic necrosis characterized by loss of hepatocytes and

an influx of eosinophilic material (oedema) into the vacant space admixed with low number of both degenerate and non-degenerate neutrophils.

The examined livers of rats in group IV received lambda cyhalothrin plus vit.c showed mild congestion of portal and central vein the portal areas were expanded by moderate number of inflammatory cells mainly lymphocytes in some cases (photo 3).

Kidney of rats in the control group and group II (rats received vitamine C) showed no histopathological findings Normal histological structure of the glomeruli and tubules in the cortex of kidney were recorded. After fourth week the examined kidneys of rats in group III (received lambda cyhalothrin), revealed congestion of cortical blood vessels and intertubular capillaries accompanied by edema and mild inflammatory cellular infiltration of the perivascular interstitium mainly lymphocytes, plasma cells and macrophages. Periglomerular lymphocytic cellular aggregation was also observed in some cases. The renal tubules in the renal cortex showed degenerative changes of their lining epithelium which exhibited vacuolar and hydropic degeneration (photo 4). While after 8th week the examined kidneys of rats in group III received lambda cyhalothrin revealed congestion of some renal blood vessels and intertubular capillaries (photo 5) with prevascular mononuclear macrophage. Moreover, large area of lytic necrosis characterized by loss of some renal tubules and an

influx of erythrocytes and eosinophilic material (oedema admixed with cellular debris and low number of inflammatory cells into the vacant space were also detected in the few cases in renal cortex (photo 6). The microscopical examination

of rats in group IV received lambda cyhalothrin plus vit.C. revealed mild cysts dilation of some renal tubules lined by attenuated epithelium in some cases (photo 7).

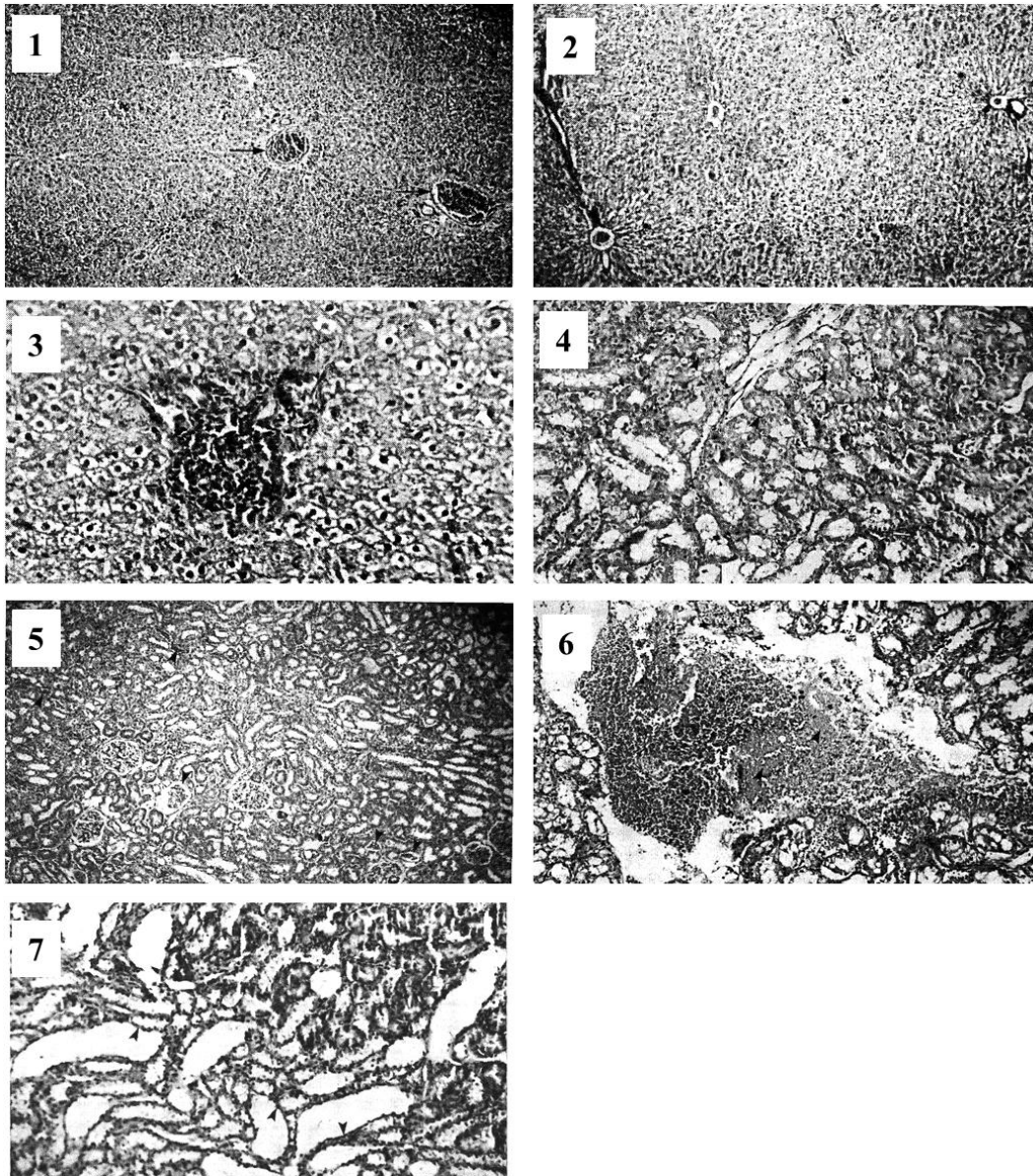


Photo. (1): Liver of rat treated with 100 mg lambda cyhalothrin / Kg. B. Wt for one month (Group I 11) showing dilatation and congestion of the portal veins (arrow). H&E stain x 100. Photo (2): Liver of rat treated with 100 mg lambda cyhalothrin / Kg. B. Wt for two months (Group III) showing large areas of degenerative changes of hepatocytes. H&E stain x 100. Photo. (3): Liver of rat treated with 100 mg lambda cyhalothrin / Kg. B. Wt and vitamin C for one month (Group IV) showing portal area expanded by moderate numbers of inflammatory cells mainly lymphocytes (arrow head). H&E stain x 400. Photo. (4): Kidney of rat treated with 100 mg lambda cyhalothrin LC17 Kg. B. Wt for one month (Group III) showing vacuolar and hydropic degeneration (arrow head) of the lining epithelium of some tubules in renal cortex. H&E stain x 200. Photo. (5): Kidney of rat treated with 100 mg lambda cyhalothrin / Kg. B. Wt for two months (Group III) showing congestion of some renal blood vessels and intertubular capillaries (arrow head). H&E stain x 100. Photo (6): Kidney of rat treated with 100 mg lambda cyhalothrin / Kg. B. Wt for two months (Group III) showing large area of lytic necrosis characterized by loss of some renal tubules and an influx of erythrocytes (asterisk) and eosinophilic material (arrow head) admixed with cellular debris and low numbers of inflammatory cells into the vacant space. H&E stain x 200. Photo. (7): Kidney of rat treated with 100 mg lambda cyhalothrin LCT/ Kg. B. Wt and vitamin C for two months (Group VI) showing cystic dilatation of some renal tubules lined by attenuated epithelium (arrow head). H&E stain x 200.

4. DISCUSSION

Lambda cyhalothrin is a broad spectrum pyrethroid insecticide cause physiological, biochemical, and behavioral dysfunctions in laboratory animals, including growth rate of body, haematopiotic system, kidney, liver and reproductive system.

Vitamin C. was tested for its potential to reduce lambda cyhalothrin toxicity in male albino rats.

Regarding to the effect of lambda cyhalothrin on erythrogram of rats as shown in Table (1). The rats in group III, (rats received lambda cyhalothrin) showed significant decrease in RBC^S count, Hb concentration and PCV in compared with other experimental groups after 4th and 8th weeks. The damage effect of lambda cyhalothrin on erythrocyte was found due to reactive oxygen species (ROS) [1]. Erythrocytes are particularly sensitive to oxidative damage due to presence of high poly unsaturated fatty acids content in their membranes and high cellular concentration of oxygen and hemoglobin. The erythrocytes can be oxidatively damaged due to exposure to toxic chemicals (lambda cyhalothrin) [23].

Lambda cyhalothrin in rats was increase the number of structural chromosomal aberration (SCA) and frequency micronucleated (MN) erythrocytes [7]. The pyrethroid induce the oxidative damage in the terms of alterations in the enzymatic defense system in erythrocytes [8, 14, 24]. There was no statistical differences in RBCs count, Hb concentration and PCV % in rats of group II (rat received vit. C in drinking water) and rats in group IV (rats received lambda cyhalothrin plus vit. C.) after 4th & 8th week but the rats in group I (control) showed significant increase in PCV% in compared with other experimental group. Vitamin C (antioxidants) can protect against the damage effect of erythrocyte derived reactive oxygen species (ROS) [1]. Vitamin C inhibits the radical generation could further reduce the oxidative effect

caused by lambda cyhalothrin [5, 15]. Vit. C is well known as an antioxidant; which act as an electron donar to protect the body from radicals and pollutants [17]. Vit C is a water-soluble essential nutrient and it is perhaps the most important antioxidant in extra cellular fluid [11]. In addition the non-significant increase of RBCs count, Hb concentration and PCV% of vit .C treatment rats could be due to the lowered lipid peroxide level in RBC's membrane leading to a decreased susceptibility of RBC's to hemolysis.

In the present study, significant increase in ALT, AST and AP was observed in group III administrated lambda cyhalothrin (as shown in Table 5) which might be due to increased cell membrane permeability or cell membrane damage of hepatocytes caused by lambda cyhalothrin. These findings are in accordance with previous studies [3, 10, 14, 24-26, 32]. These results confirmed by histopathological findings of liver at were 4th and 8th week of experiment (Photo 3) that showed vacuolar and hydropic degeneration of the hepatocytes. The exposure to lambda cyhalothrin cause increase in free radical reactive oxygen species (ROS). The free radicals cause reduction of GST activity, transaminases (AST & ALT) and acid phosphatas [31]. The rats administrated lambda cyhalothrin for 2 month at dose 150mg/kg B.w, showed significant increase of transminase enzymes alanine amino transferase (ALT) and asperatate amino transferase (AST). [10, 13]. In the present study levels of liver marker enzymes (ALT, AST and AP) were decreased significantly by treatment of vit C. These effects were mainly related to antioxidant effect of the vit. C. Previously performed clinical and experimental investigations have shown that the vit C. has protective effect against oxidative damage [14].

Regarding to the effect of lambda cyhalothrin on serum total protein, albumin and globulin in group IE, (as shown in Table 6). There were significant

decrease in total protein, albumin and globulin at 4th and 8th week of experiment. These result agreed with [12], [7]. Lambda cyhalothrin lowered transcripti3onal activity of rRNA genes and inhibited the specific activity of paired nucleoli in fine cells [9] recorded that the administration of lambda cyhalothrin in rats, showed decrease in protein carbonyl level. Lambda cyhalothrin cause increase the generation of reactive oxygen species and DNA damage levels that induce adverse immune effect [33]. In our results, there was no statistical differences in total serum protein, albumin and globulin between group I, rats non treated and group II, rats received vit. C that showed the higher level of total protein, albumin and globulin followed by there parameters in group IV rats received lambda cyhalothrin plus vit. C. The improvement of serum total protein, albumin and globulin may be attributed to that vit C. as it was act to overcom the oxidative stress of lambda cyhalothrin [15]. L-ascorbic acid (vit. C) is a well-known antioxidant, which functions as an electron donor to protect the body from radicals and pollutants. Antioxidant can be water soluble or lipid soluble, therefore found in both lipid and water portion of cells, protecting vital bimolecules such as proteins and DNA from being oxidized by the free radicals [11].

Concerning to the effect of lambda cyhalothrin the levels of serum urea, uric acid and creatinine of rats group HI rat recived lambada cyhalothrine (as shown in Table 7), there were significant increase in levels of serum Urea, Uric acid and creatinine in compared to other groups. These results are full agreement with (2, 8, 26]. Increase in creatinine concentration might be due to loss of kidney function and considered as functional evidence of lambda cyhalothrin induced nephrotoxicity [9]. The decrease activities of antioxidants enzymes super oxide dismutase (SOD), Catalase (CAT), glutathione reductase (GR) and glutathione transferase (GST)

were observed in the renal tissues, which indicated the failure of antioxidant defense system to overcame the influx of ROS induced by lambda cyhalothrin exposure [6]. Necrosis of tubular epithelium, cloudy swelling of epithelial cells of renal tubules, narrowing of tubular lumen, contraction of glumerulus and expression of space inside Bowmam's capsule were observed after exposure of lambda cyhalothrin [29]. These results were confirmed by histopatho logical findings of kidney (Photo 17), that showed degeneration and necrosis of the endothelial cells lining the tubules.

In the present study, there were no statistical differences in levels of urea, uric acid and creatinine in serum of rats between group I (control) and group II rats received vit. C. While the levels of urea, uric acid and creatinine in serum of rats group IV (rats received lambda cyhalothrin plus vit C) were higher than that of group I (control) and group II (rat received vit C.). The improvement marked in the level of serum urea, uric acid and creatinine in group IV revealed to soluble water antioxidant vit C- and there results agreement with Makni [20].

5. Conclusion

Lambda cyhalothrin had adverse effect on hemopiotic system. Lambda cyhalothrin is a potent toxic substance that cause changes in liver and renal functions and alter the histological structure of organs (liver, kidney). Lambda cyhalothrin reduced the concentration of total protein, albumin and globulin. Vitamin C have be shown to be effective against lambda cyhalothrin induced toxicity. It showed marked improvement in lambda cyhalothrin induced hematological and biochemical alterations and tissue damage. Also it improves the body weight.

6. REFERENCES

1. Backer, A.S., smith, M.S. Michael S.D. person F.G. and Darkrerio S. 1996.

- Effects of experimentally induced chronic hyperpolainemia on testosterone and gonadotropin levels in male rats and Mice. *J Endocrinol* **49**: 311-316
2. Banchroft, J.D, Stevens, A. and Turner, D.R. 1996. Theory and practice of histological techniques 4th ed. Churchill living stone, New York, London, San Francisco, Tokyo.
 3. Banerjee, B.D. Seth, V. and Ahmed, R.S. 2001. Pesticide induced oxidative stress. *Toxicological. Lett.* **82/83**: 933-940.
 4. Belifield and gold berg 1971. Alkaline phosphate standar and measurement of serum alkaline phosphates enzymes. *Enzyme* **12**: 561-566.
 5. Butterfield, D.A., Koppal, T., Howard, B., Subramanian, R., Hah, N. and Hensley, K. 1998. Structural and functional changes in proteins induced by radical oxidative stress of Lambada cyhalothrine and protective action of antioxidants. *Acad. Sci.* **854**: 448-462.
 6. Calviello, G., Piccioni, E., Boninsegna, A., Tedesco, B., Maggiano, N., and Serini, S. 2006. DNA damage and apoptosis induction by the pesticide Mancozeb in rat cells: involvement of the oxidative mechanism. *Toxicol. Appl. Pharmacol.* **211**: 87-96
 7. Celik, A., Mazmanci, B., Cannlca, Y., Comeleköglü, Ü. and Askin, A.H. 2005. Evaluation of cytogenetic effects of lambda-cyhalothrin on wistar rat bone marrow by gavage administration. *Ecotox. Environ Safe.* **16**: 128-133.
 8. Chees brough, M and Arther, M.C. 2006. Effect of Lambada cyhalothrine on certain haematological parameters. *Exotoxicol, Environ Safe.* **58**: 226-238.
 9. Crow, J.A .Kerestin, L and Splinter, F.K 2009. Oxidative stress of lambda cyhalothrin on male rat kidney and protective role of ascorbic acid. *Trop Anim Health Prod.* **26**: 7-12
 10. Dahama, S. and Harzallah, D. 2009. Effect of Lambada cyhalothrine in liver enzyme. *Food Chem Toxicol.* **43**: 299-203.
 11. El-Demerdash, P.M. Yousef, M.I. and Zoheir, M.A. 2005. Stannous chloride induces alterations in enzyme activities, lipid peroxidation and histopathology in male rabbit, antioxidant role of vitamin C. *Food Chem. Toxicol.* **43**: 1743-1752.
 12. Fahmy, A.M. and Abdala, E.F. 2001. Cytogenetic effects by natural pyrethrin and the synthetic lambda Chyhalothrin in mice in vivo. *Cytologia* **66**:134-149.
 13. Fetoui, H., Garoui, E., Makniyadi, F. and Zaghal, N. 2008. Oxidative stress induced by lambda cyhalothrin (LCT) in rat erythrocytes and brain, Attenuation by vitamin C. *Environ. Toxicol. Phar.* **26**: 225-231.
 14. Fetoui, H., Makni, M., Garoui, E. and Zaghal, N. 2010. Toxic effects of lambda-cyhalothrin, a synthetic pyrethroid pesticide, on the rat kidney: Involvement of oxidative stress and protective role of ascorbic acid. *Exp. Toxicol. Pathol.* **62**: 593-599.
 15. Evans, P. and Halliwell, B. 2001. Health risk from pyrethroid and their neurotoxicity. Toxicokinetic and human disorder. *Wiss. Umw.* **85**: 567-574.
 16. Husdan, H. and Rapaport, A. 1968. Estimation of creatinine by the Jaffe reaction. *Clinic Chemist* **14**: 222-226.
 17. Igbal, K. Khan A., and Khattak M.M.A.K. 2004. Biological significance of ascorbic acid (vitamin C) human health. *Pak. J. Nutra.* **3**: 5-13.
 18. Kaplan, L.A and Presce, A.J. 1996. The effect of synthetic pyrethroid in rat somatic and sex cells depending on exposure route. *Roez. Pantsw. Hig.* **52**: 65-89.
 19. Leahey, D.P. 1985. Pyrethroid Insectides is analogs of naturally occurring pyrethrine and widely used in agriculture in many countries. *Exp. Toxicol Pathol.* **65**:134-54.
 20. Makni, M. 2009. Lambda cyhalothrin induce bio chemical and histo pathological change in kidney of male rat. *Exp. Toxicol. Pathol.* **61**:189-96.
 21. Manca, F. 2002. Toxic effect of lambada cyhalothrine on male albino rat at dose orally 150mg/kg B.w. daily for one week. *Arch Toxicol.* **75**: 410-413.
 22. Meister, R.T 1992. Chemical & physical properties of lambda cyhalothrin. International Register of Potential Toxic Chemicals (IRPTC) and other united nation source.
 23. Nasuti, C. Cantalamess, F. Falcioni, G. and Gabbia nelli R. 2003. Different

- effects of type I and II pyrethroids on erythrocyte plasma membrane properties and enzymatic activity in rats *Toxicology* **191**: 233-244.
24. Prasanthi, K. Muralidhara and Rajini, P.S. 2005. Morphological and biochemical changes in rat erythrocytes after administration of lambda cyhalothrin. *Toxicology in vitro* **19**: 449-456.
 25. Rickard, J. and Brodie, M.E. 1985. Correlation of blood and brain levels of neurotoxin parathyroid deltamethrin with onset of symptoms in rats. *Pestic. Biochem. Physiol.* **23**: 143-156.
 26. Soderlund, D.M. Clark, J.M., Sheets. L.P., Mullin, L.S. Piccirillo, V.J. and Sergeant, D. 2002. Mechanism of pyrethroid neural toxicity implications for cumulative risk assessment. *Toxicology* **171**: 53-59.
 27. Schumann, G. and Kaluke, R. 2003. Reduction in libido and fertility of male rats after administration of lambda cyhalothrin. *Int J Androl.* **23**: 165-187.
 28. Us Environmental Protection (U.S EPA) 1988. Properties of Lambda cyhalothrine and its uses. *Med. Sc. Monti.* **16**: 245-249.
 29. Velmurugan, B., Selvanayagam, M., Cengiz, E.I. and Unlu, E. 2007. Histopathology of lambda-cyhalothrin on tissues (gill, kidney, liver and intestine) of *cirrhinus mrigala*. *Environ. Toxicol. Phar.* **24**: 286-291.
 30. Yavuz, T. Delibas, N. Yildirm. B., Altuntas, I. Candir, O. Cora, A., Karahan, Ibrisim N. and Kustal, E. 2004. Vascular wall damage in rats induced by methidation and ameliorating effect of vitamin E and C. *Hum. Exp. Toxicol.* **78**: 655-659.
 31. Yousef, M.I., Kamil, K.I., El-Guensi, M.I. and El-Demerdasb, E.M. 2007. An in vitro study on reproductive toxicity of aluminum chloride on rabbit sperm: the protective role of some antioxidants. *Toxicology* **239**: 213-223.
 32. Yousef, M.I. 2010. Vitamin E modulates reproductive toxicity of pyrethroid lambda-cyhalothrin in male rabbits. *Food Chem. Toxicol.* **48**: 1152-1159.
 33. Zhang, Q., Wang, C., Sun, L., Li, L. and Zhao, M. 2010. Cytotoxicity of lambda-cyhalothrin on macrophage cell line RAW 164-7. *J. Environ. Sci.* **22**: 428-432.